

Large Animal VETERINARY Rounds™

MAY 2003
Volume 3, Issue 5

AS PRESENTED IN THE ROUNDS OF THE DEPARTMENT OF LARGE ANIMAL CLINICAL SCIENCES
OF THE WESTERN COLLEGE OF VETERINARY MEDICINE, UNIVERSITY OF SASKATCHEWAN

Equine Dentistry – Moving into the 21st Century

James Carmalt, VetMB, MVetSc, and Dennis Rach, DVM

New research and techniques pertaining to equine dentistry have recently been published or are in the clinical trial phase. These are based upon a solid foundation of anatomy and physiology. This edition of *Large Animal Veterinary Rounds* highlights these advances, reinforces the importance of the complete oral examination, describes the evaluation of rostral-caudal movement of the mandible and how to use it, and explores the definition and treatment of equine diastema. The different methods of treating cheek tooth alveolitis are also discussed.

Introduction

Equine dentistry has been practised since at least 600 BC. By the time of Aristotle (330 BC), ageing horses by their teeth and the effects of periodontal disease had been described and treatments postulated. Despite this early beginning, knowledge progressed slowly, inhibited by the lack of the printing press and rapid means of communication. It was not until the mid-17th century that Markham (1610-1723) described a technique to remove sharp lateral edges of the upper arcade to prevent soft tissue ulceration; this practice remains the most common dental procedure performed in the horse.¹

Because of poor communication and unreliable methods for evaluating procedures, many errors found their way into common practice and misinterpretations still confound the literature today. For example, the ageing of horses by their teeth remains a common procedure, but it is an important cause of litigation. A recent editorial on the subject, at least partly backed by clinical evidence, suggested that you should "...not look a gift horse in the mouth, because if you do, you won't discover how old it is with any accuracy."² There is only one published, randomized, blinded, clinical trial examining the effect of dental correction on weight gain in horses despite a significant number of anecdotal reports of its benefit.³ There is no proof that poor dentition leads to "choke" or impaction colic. Other than the lack of dental overgrowths on fossil equine teeth, there is also no proof that the dental abnormalities endured by modern horses are a product of domestication, since a study of wild or minimally managed equine populations is lacking.

The knowledge of equine dental embryology, anatomy, and physiology has undergone a revolution in the last 30 years, allowing evidence-based decision-making to affect clinical procedures. Equine dental terminology has not changed greatly (Table 1, Figure 1); however, recently there has been a standardization of tooth identification using the Triadian system. In this system, each tooth is identified using a three-digit number. Arcades are numbered 1 through 4 clockwise beginning at the top right (as the operator views the horse). Incisors, from central to lateral, are numbered from 01-03 and then the canine, wolf tooth and cheek teeth are incrementally numbered up to 11. Thus, the third molar on the bottom right arcade is Triadian # 411.



WESTERN COLLEGE OF
VETERINARY MEDICINE



Department of Large Animal Clinical Sciences Western College of Veterinary Medicine

Jonathan M. Naylor, DVM, Diplomate ACVIM
(Editor)
Charles S. Rhodes, DVM, MSc (Dean)
Lyall Petrie, BVMS, PhD (Acting Dept. Head)
Ken Armstrong, DVM, Professor Emeritus
Sue Ashburner, DVM
Jeremy Bailey, BVSc, Diplomate ACVS
Spence M. Barber, DVM, Diplomate ACVS
Albert D. Barth, DVM, Diplomate ACT
Frank Bristol, DVM, DACT, Professor Emeritus
Ray Butler, DVM, Professor Emeritus
John Campbell, DVM, DVSc
Claire Card, DVM, DACT
Terry D. Carruthers, DVM, PhD
Bill Cates, DVM, Professor Emeritus
Chris Clark, VetMB, MVetSc
Peter B. Fretz, DVM, Diplomate ACVS,
Professor Emeritus
Paul Greenough, DVM, Professor Emeritus
Jerry Haigh, DVM, Diplomate ACZM
Eugene D. Janzen, DVM, MVS
Steve Manning, DVM, Diplomate ACT
Reuben J. Mapletoft, DVM, PhD
Kelly MacLellan, DVM
Colin Palmer, DVM, Diplomate ACT
Andre Palasz, MSc, PhD
Jag Patel, DVM, Diplomate ACT
O.M. Radostits, DVM, Diplomate ACVIM,
Professor Emeritus
Fritz J. Schumann, DVM, MVetSc
Joseph M. Stookey, PhD
Hugh G.G. Townsend, DVM, MSc
Cheryl Waldner, DVM, PhD
David G. Wilson, DVM, Diplomate ACVS
Murray R. Woodbury, DVM, MSc

Western College of Veterinary Medicine Department of Large Animal Clinical Sciences

52 Campus Drive
University of Saskatchewan
Saskatoon, Saskatchewan S7N 5B4

The editorial content of *Large Animal Veterinary Rounds* is determined solely by the Department of Large Animal Clinical Sciences, Western College of Veterinary Medicine



The Canadian Veterinary Medical Association recognizes the educational value of this publication and provides support to the WCVM for its distribution.

Table 1: Common dental abnormalities	
Terminology	Explanation
Hook	Up to 1/3 of occlusal surface of tooth projects ventrally beyond the occlusal surface. Almost exclusively a problem with the maxillary molars. Upper first 06's most often affected.
Ramp	Up to 1/3 of occlusal surface of tooth projects dorsally beyond the occlusal surface. Almost exclusively a problem with mandibular molars. Lower 11's most commonly affected.
Stepped	Greater than 1/3 of the tooth is raised above the level of the surrounding occlusal surface. Any cheek tooth may be affected. Most often found in association with cups in the opposing molar.
Cups	In these teeth, only the cementum layer remains. Most often associated with aged horses or extreme wear. Reduction in occlusal pressures allows the opposing tooth to overgrow, leading to the formation of a stepped tooth.
Transverse ridge	Enamel ridges running at 90° to the long axis of the tooth in a buccolingual direction are normal findings. However, if due to a malocclusion, they become excessively tall, inhibition of rostro-caudal motion may result.
Diastema	An abnormal gap between cheek teeth, which may be congenital or acquired.

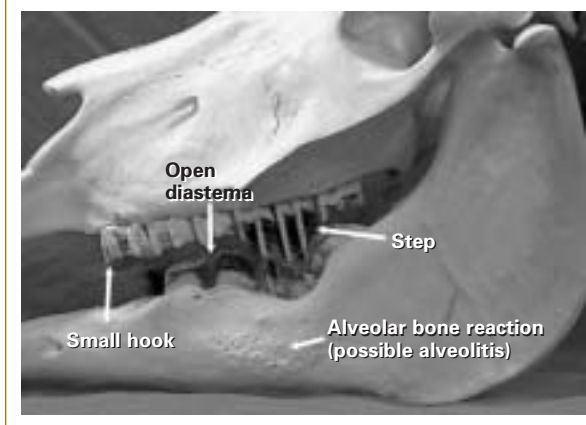
The advent of equine power dentistry, combined with sedative drugs, has changed the way we view the treatment of dental problems. Floating teeth no longer needs to be laborious, hot, frustrating work. With a competent team of helpers to “set-up” the horses, it is possible to perform as many as 70 routine floats in one day. In equine dentistry, just as in general veterinary medicine, the adage, “first do no harm” is all the more important since the majority of decision-making is based upon anecdotal reports and hearsay.

The oral examination

The importance of a complete oral examination in horses suspected of having dental problems has been reiterated many times. However, it is important to note that some dental pathology may not be appreciated during the physical examination and that other diagnostic tests may be necessary.

In the case of weight loss, a complete physical examination must be carried out, in addition to a specific oral examination, to attempt to rule-out neoplasia, parasitism, or

Figure 1: Some common dental abnormalities



other systemic disease, as well as checking the cardiovascular status of the patient prior to sedation.

A complete oral examination of the horse requires sedation. The veterinarian is responsible for the physical safety of the personnel handling the horse and its well-being. Horses can respond unpredictably to oral examination and mouth gags can be dangerous. For these reasons, we recommend that the owner does not handle the horse. An initial examination of the mouth can be performed without sedation; however, important pathology can be missed.

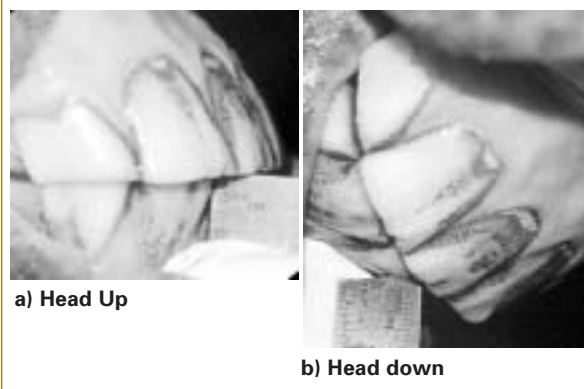
An oral examination is not complete unless all teeth, including the occlusal surfaces of the premolars and molars, are visually examined and palpated. This requires a full mouth speculum and the horse's head should be held, either by a competent technician or in a dental halter. A full mouth speculum weighs approximately 2.5 kg and, at the end of a horse's nose, this can be a formidable weapon without sedation.

It is advisable to wear a headlamp and examination gloves at all times to facilitate the examination of the equine mouth and to protect from the small, but potentially devastating, risk of rabies. The steps in an oral examination are as follows:

- The horse is sedated with a combination of short- and longer-acting tranquilizers and the addition of a narcotic for analgesia. In most cases, an appropriate combination for a 500-kg horse is an intravenous dose of 200 mg xylazine, 25 mg acepromazine, and 10 mg butorphanol. The mouth is lavaged using a dosing syringe.

- The amount of rostro-caudal mobility is determined by lifting the head until the mandible is parallel to the ground and measuring the degree of overbite, then flexing the head at the poll and measuring the amount of underbite. The difference between the two is the rostro-caudal mobility (RCM, Figure 2).

Figure 2: Measurement of mandibular rostro-caudal mobility

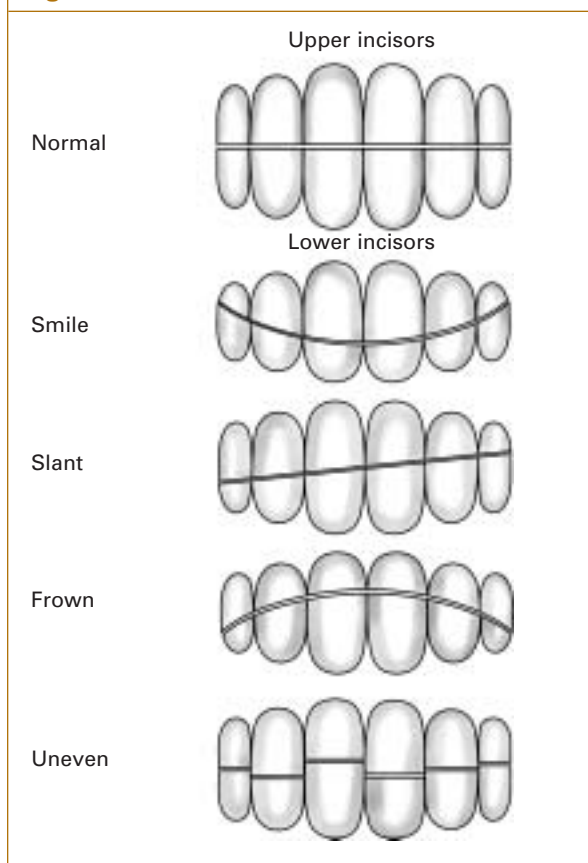


- The incisor arcades are examined to determine whether malocclusion is present. These include smiles, slants, frowns or uneven teeth (Figure 3).

- A full mouth speculum is placed and opened. At this point, it is common to grasp the tongue to assist inspection of the caudal teeth, although this is not usually necessary. Grasping the tongue leads to a reflex withdrawal reaction and contraction of the internal glossal musculature. The result is a dorsal thickening and a sigmoid latero-medial bend in the tongue that further reduces visibility. The medial and occlusal aspects of the dental arcades are observed, followed by examination of the lateral aspect. Direct observation of the lateral edges is not necessary to determine the presence of points; this can be deduced if dimpling of the soft tissue of the cheek or ulcers are seen. Observation may be improved by decreasing the separation of the incisors with the speculum, allowing greater space between tooth edges and internal cheek surface. This is usually necessary during power floating to allow access to the caudal cingulae (lateral ridge) of the last upper molar.

- Observation is followed by manual examination using a wet, jewellery-free hand and arm. One hand remains outside the mouth exerting caudal pressure on the speculum. This serves to reduce the chance of the horse opening its mouth and slipping from the speculum and additionally, acts as a lever to assist rapid withdrawal of the arm in the event of an accident. The occlusal surfaces of all teeth are palpated for the presence of excessive transverse ridges, stepped teeth, or cups. Areas of trapped feed material are removed and smelled to detect putrefaction; the underlying gingiva is gently palpated. All teeth are grasped latero-medially, rocked and assessed for looseness. In some cases, this must be repeated while observing the tooth, since the movement can be so small that it may only be seen as a slight movement of the water meniscus at the tight space between the teeth. Slight movement is noted on the examination form and rechecked at subsequent oral examinations.

Figure 3: Common incisor malocclusions



- If teeth exhibit areas of decay or if diastemata between teeth are present (see below), a more in-depth examination of that area can be performed using an angle mounted mirror and a bent, blunt-ended needle attached to a 12 cc syringe containing water. This allows the removal of debris and the detection of pathologies such as patent infundibulae.

- Once complete, the practitioner shows the client the abnormalities detected and performs the necessary dental procedures. The client is then invited to view the finished work to demonstrate that the problems have been addressed. This helps involve the client and may reduce complaints about the bill.

The examination procedure presented above appears lengthy, but can usually be performed in 3 to 5 minutes.

Routine dental floating

There are numerous review articles and chapters in textbooks describing the correct techniques for routine manual dental floating.¹ Floating is the most common dental procedure performed in the horse. The purpose of this is to maintain the symmetry and balance of the arcades and allow a free, elliptical chewing motion,⁴ which may improve feed digestion or the performance of the horse.

There are many anecdotal reports supporting the theory that dentistry has an integral role in horse performance. In addition to removing sharp lateral edges, which can cause cheek ulcers and wolf teeth, and may lead to bit-aversion, reduced mandibular movement may have a performance-limiting effect (See the section on rostro-caudal motion of the mandible, below).

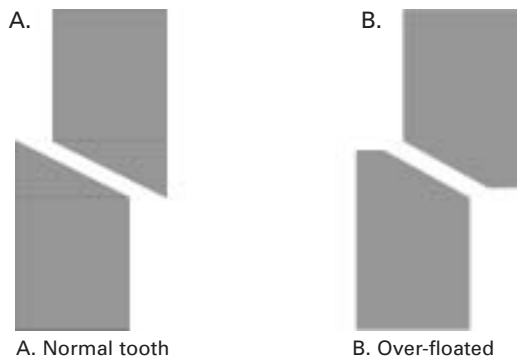
Weight loss has been attributed to poor dentition in the horse, as have choke and impaction colic. Although it is still generally accepted that floating is beneficial in horses that have oral trauma secondary to tooth problems, there is no evidence that routine floating improves feed intake or digestion in horses. Ralston et al³ examined the effect of manual dental correction on weight gain and feed digestibility in 8 horses and found no significant difference between control and floated horses. At the WCVM, we randomly assigned 56 horses to one of 4 feeding groups (hay alone, hay and oats, hay and soy pellet, hay and canola pellet) and each group was further sub-grouped into floated and non-floated controls. In this study, feed group significantly affected weight gain, however, floating did not (Carmalt et al, unpublished data). Many clinicians change the diet of a thin horse as well as floating the teeth. In these circumstances, it may be that the diet change and not the dental floating contribute to the weight gain.

Over floating

As power dental instruments become increasingly available, it is easier for the veterinary dentist to remove tooth material much more rapidly. In some instances, too much tooth may be removed. Anecdotal reports suggest that incisor reduction – reducing the height of the incisors by grinding – may be commonly performed by para-professionals, as well as by qualified veterinary dentists. However, our experience suggests that it is only indicated in a small number of horses. At the WCVM in 2001–2002, approximately 600 complete dental floats were performed. Only 2 sets of incisors were reduced to correct malocclusion during this time. The literature states that a 1 mm reduction in incisor length will lead to a 3 mm reduction in inter-occlusal distance between the cheek teeth.⁵ Overzealous incisor reduction can lead to molar occlusion at rest, which is abnormal. There is concern that this can lead to temporo-mandibular joint pain. It is likely that in the long-term, over-reduction of the incisors will result in greater molar wear or the need to reduce the height of the erupted crown of the cheek teeth to allow prehension of feed.

Another potential problem with over-floating is a reduction in the molar angle of occlusion (MOA). There is experimental evidence suggesting that reduction of

Figure 4: The effect of overfloating



Note that by over-floating, the width and therefore, surface area, of the cheek tooth available for shearing feed is markedly reduced.

the MOA by overzealous floating may impair fiber digestion³ (Figure 4). This may be due to a reduced surface area for grinding the feed. This situation also occurs when cheek teeth are over-floated.

Mandibular cheek tooth alveolitis

Cheek tooth alveolitis, (tooth root infections, mandibular periapical disease) is one of the most common and easily recognized dental conditions. Affected horses often present with mandibular swellings that are discrete, smooth, often painful, hard lumps. These must not be confused with “eruption cysts.” Eruption cysts are usually painless, bilateral, and symmetrical. They are a physiological response of the alveolar sac to the eruption of the permanent pre-molar teeth and are not necessarily associated with retained “caps.” Alveolitis can occur due to migration of oral bacteria through damaged gingiva, periodontal disease in mature horses, or a patent infundibulum during dental eruption in young horses. Radiology is the most useful diagnostic aid to differentiate between an uninfected eruption cyst and alveolitis disease.⁶ In the former case, the outline of the dental sac is usually distorted and irregular due to the peripheral deposition of smooth, well-organized, new bone. In the latter case, disorganization of the alveolar bone occurs and, in advanced cases, the affected roots may be distorted or destroyed. Contrast radiography can be useful if a draining tract is present.

There are a number of ways to treat alveolitis. Treatment of confirmed periapical disease using systemic antimicrobials is often of little use. Drainage tracts may seal over during the period of treatment, only to re-open at the cessation of therapy. Successful treatment of periapical disease usually follows one of three routes.

Exodontia (tooth removal)

The tooth can be removed, either through the mouth or surgically, under general anesthesia. There are important negative sequelae to removing cheek teeth in mature horses, one of which is a lifetime of follow-up dental care to control the continued eruption of the opposing tooth. The dental arcade of the horse responds to tooth removal by mesial drift; cheek teeth, caudal to the space left by tooth removal will migrate forward leaving spaces, or diastema, between the molars. These may become sources of periodontal disease. In addition, surgical tooth removal in the horse is not an innocuous procedure; the immediate complication rate is described as approaching 50%,⁷ with problems that include fractured teeth, removal of the wrong tooth, sequestration, and fistula formation.

For these reasons, tooth retention is preferred to removal. Tooth retention in the face of infection requires an intact periodontal ligament and no significant periodontal disease; this can be investigated during the course of a complete oral and radiographic examination.

Endodontics (root canals)

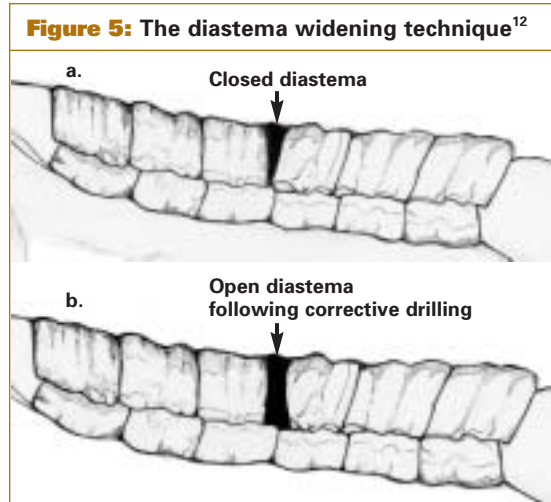
Endodontics, including extirpation of the pulp cavity, obturation, and root-end closure can be performed in the horse; however, this procedure is not commonly employed due to the high failure rate and the lack of expertise and instrumentation. Another problem is that pulp canals in the equine cheek tooth form interconnecting anastomoses for up to 3 years post-eruption. For the 4th premolar, this equates to a horse age of 7 years. After this time, each pulp canal is distinct, the roots are completely formed,⁸ and endodontics are possible.

Apicoectomy

Horses with mandibular periapical disease without periodontal disease can be treated by apical resection through the ventral surface of the mandible with the resultant wound left to heal by second intention. The horse is placed under general anesthesia and, using radiographic guidance, the affected roots are located. A skin incision is made and the periosteum reflected. The ventrum of the mandible is opened using an air-driven burr and an apical resection of the root performed. The wound is subsequently treated using standard open-wound management. Of 15 horses treated in this fashion, 13/15 remain free of infection at the current time, 2/15 required tooth removal after failure of this treatment method (Barber, unpublished data).

Diastemata

A diastema is an abnormal gap between teeth.⁹ This definition excludes the interdental space, or



a) Cheek tooth arcade showing a close diastema
b) Cheek tooth arcade showing an open diastema created by drilling

bars of the mouth, which is normal in herbivores. Diastemata (pl.) can be further subdivided into open or closed (valved).¹⁰ The former often cause no clinical problem other than permitting local dental overgrowth in the opposing teeth due to a lack of wear. These are non-painful and although they may be feed-packed during oral examination, removal of the feed should not reveal gingival recession, pathology, or pain on palpation. Approximately 15% – 20% of all horses presenting to the WCVM for oral examination have this form of diastema.

The closed or valved diastema is one in which the rostral and caudal boundaries are triangular in shape and the opening on the occlusal surface is extremely small, compared to the base. These trap feed and cause putrefaction with resultant periodontal disease characterized by gingival recession and hyperemia. Despite heavy sedation, affected horses will often react violently to simple gingival pressure. Different techniques have been used to treat this condition. Simply removing trapped feed is not curative since food impaction rapidly recurs. Feed may be removed using a slurry of medical grade baking soda and water under pressure, and the interdental space packed with a dental amalgam to prevent feed retention.¹¹ An alternative treatment is to convert the triangular shape into a U-shape by drilling with a specially designed set of diastema burs. This removes the impedance to egress and feed material can cycle through the space without putrefaction, allowing gingival healing (Figure 5).¹²

Rostro-caudal motion of the mandible

The majority of normal horses (ie, free of developmental or acquired dental abnormalities) have a maxillary overbite when their mandibles are held

parallel to the ground. If the head is flexed at the poll, the mandible drops rostrally in the temporo-mandibular joint (TMJ), which may lead to the presence of a mandibular underbite. Recently, 3-dimensional kinematic analysis of the equine TMJ documented a 6 mm rostro-caudal movement of the mandible during the chewing cycle of normal, light-breed (Quarter) horses.^{13,14} In heavy-breed horses, mean mobility approached 9 mm.¹⁴ Mandibular mobility has also found to be increased by dental floating in horses that never had dental work performed.

When the equine incisors are in contact, there is no molar apposition. Normally, lifting and lowering the head allows sliding of the incisors relative to one another. If tooth pathology allows opposing molars to touch, then incisor movement will be limited. It is postulated that if a horse is ridden using a standard bit, with a nose-band to prevent it from opening its mouth, poll flexion will cause significant pressure in the TMJ and, since the mandible is prevented from dropping in the normal manner, the horse will respond abnormally. This is purely conjecture; however, anecdotal evidence from some riders and trainers attest to the benefits of the removal of oral abnormalities that might reduce rostro-caudal mobility of the mandible.

Conclusion

Equine dentistry remains predominantly an art, not a science. There is still much to be learned. While many horses may have been examined, it is not uncommon to require help or guidance from other members of the profession who may have differing views on how to achieve the common goal. The use of power dental equipment has revolutionized the performance of equine dentistry; however, the skills of the basic oral examination and the challenge of keeping current with new literature and techniques are paramount to prevent excessive and incorrect use of this powerful tool.

Dr. James Carmalt graduated from Cambridge University in 1998. After an internship in large animal medicine and a year in general practice in Australia, he came back to Canada to start a residency in equine practice at the Western College of Veterinary Medicine that will finish in July 2003. He will continue as a large animal surgery resident during which time he hopes to continue to develop his interest and skills in the area of equine dentistry.

Dr. Dennis Rach graduated from the WCVM in 1970. He began to practice at Moore and Co. in Calgary in 1970 and has been a partner in that practice since 1972. His practice activities primarily include lameness and dentistry. He designs equine dental equipment.

References

1. Scrutchfield WC. Dental Prophylaxis. In: Baker and Easley. *Equine Dentistry*. Philadelphia, PA: W.B. Saunders; 1999.
2. Harvey CE. Aging horses by examining the teeth- A centuries-old inexact science. *J Vet Dent* 1997;14(3):97-98.
3. Ralston SL, Foster DL, Divers T, Hintz HF. The effect of dental correction on feed digestibility in horses. *Equine Vet J* 2001;33(4):390-393.
4. Fischer D, Easley J. Floating: Making equine dentistry a practice profit center. *Large Animal Veterinarian* 1994;49.
5. Rucker BA. Utilizing cheek teeth angle of occlusion to determine incisor shortening. *Proc Am Assoc Eq Pract* 2002;48:448-452.
6. Easley J. Dental Radiography. In: Baker and Easley. *Equine Dentistry*. Philadelphia, PA: W.B. Saunders; 1999.
7. Prichard MA, Hackett RP, Erb HN. Long-term outcome of tooth repulsion in horses. A retrospective study of 61 cases. *Vet Surg* 1992; 21(2):145-149.
8. Kirkland KD, Baker GJ, Manfra Marretta S, Eurell JA, Lososky JM. Effects of aging on the endodontic system, reserve crown, and roots of equine mandibular cheek teeth. *Am J Vet Res* 1996;57(1):31-38.
9. Dorland WA. Diastema. In: *Dorland's Illustrated Medical Dictionary*, 29th Ed. Philadelphia: WB Saunders; 2000:494.
10. Carmalt JL. Understanding the equine diastema. *Equine Vet Educ* 2003; 15:34-35.
11. Greene SK, Basile T. Recognition and treatment of equine periodontal disease. *Proc Am Assoc Eq Pract* 2002;48:463-466.
12. Carmalt JL, Wilson DG. Treatment of a valve diastema in two horses. *Equine Vet Educ* 2003; In Press.
13. Bonin SJ. Three-dimensional kinematics of the equine temporal mandibular joint. MS Thesis, Michigan State University; 2001.
14. Carmalt JL, Townsend HGG, Allen A. A preliminary study to examine the effect of dental floatation on the rostro-caudal movement of the equine mandible. *J Am Vet Med Assoc* 2003; In Press.

Upcoming Meetings

9-12 July 2003

55th Annual Convention of the Canadian Veterinary Medical Association

Winnipeg, Manitoba

CONTACT: Ms. Mireille Montpetit

Tel.: 613 236-1162 ext. 23 Fax: 613 236-9681

Website: www.canadianveterinarians.net/programs

9-12 July 2004

23rd World Buiatrics Congress

Montreal, Quebec

CONTACT: www.wbc2004.ca

Do you have a review article suitable for large animal practitioners? Please contact the editor by E-mail, Jon.Naylor@usask.ca for publication and remuneration details.

Change of address notices and requests for subscriptions to *Large Animal Veterinary Rounds* are to be sent by mail to P.O. Box 310, Station H, Montreal, Quebec H3G 2K8 or by fax to (514) 932-5114 or by e-mail to info@snellmedical.com. Please reference *Large Animal Veterinary Rounds* in your correspondence. Undeliverable copies are to be sent to the address above.

This publication is made possible by an educational grant from

Schering-Plough Animal Health