

# Large Animal VETERINARY Rounds™

APRIL 2006  
Volume 6, Issue 4

AS PRESENTED IN THE ROUNDS OF THE DEPARTMENT OF LARGE ANIMAL CLINICAL SCIENCES  
OF THE WESTERN COLLEGE OF VETERINARY MEDICINE, UNIVERSITY OF SASKATCHEWAN

## Congenital and Acquired Abnormalities of the Scrotum, Testes, and Epididymides of Bulls

By Albert D. Barth, DVM, MVetSci, Diplomate ACT

Many veterinary practitioners evaluate hundreds of bulls annually for breeding soundness. As a result, it is not unusual to encounter a variety of reproductive tract anomalies and acquired pathological conditions. This issue of *Large Animal Veterinary Rounds* discusses abnormalities of the testes and epididymides.

### Conditions of the testes

#### *Testicular hypertrophy*

Unilateral testicular hyperplasia is often associated with hypoplasia or degeneration of the contralateral testis. The quality of semen from these bulls is often satisfactory and there may be little or no compromise in fertility. Hyperplasia of one testis may be due to compensatory growth, since hemicastration in normal bulls results in hypertrophy of the remaining testis. The numbers of spermatogonia, spermatocytes and spermatids, and the mean diameter of seminiferous tubules were significantly greater in hemicastrated bulls than in control bulls.<sup>1</sup>

It is common to encounter yearling bulls with surprisingly large scrotal circumference (SC) measurements in the range of 40 to 45 cm; however, the prevalence of very large testes and the effect on semen production have not been reported. Clinical presentations involving very large testes in yearling bulls may include:

- normal testicular development; normal semen at maturity
- normal testicular development; poor semen quality unrelated to testis size
- orchitis; progressing to testicular degeneration
- occlusion of the efferent ductules; testis distension followed by degeneration
- scrotal development lagging behind rapid development of large testes; testes are held too close to the body. Usually, the scrotum gradually lengthens so that by the time the bull is 18- to 24-months old the scrotum will have a neck. Some bulls may then begin to produce semen of good quality.

#### *Testicular hypoplasia*

Normally, in bulls, the individual testis weighs 200 to 500 g. An SC measurement of 35 cm corresponds to a combined testis weight of about 450 g and each additional cm adds about 37 grams to the combined weight. Hypoplasia may be unilateral or bilateral. Some authors report that most cases are unilateral and that the left side is more frequently affected,<sup>2</sup> but there appears to be no precise definition for testicular hypoplasia based on physical measurement. Histologically, testicular hypoplasia is defined based on cell populations in the seminiferous tubules. In total hypoplasia, no tubules have germinal cells, but they do contain Sertoli cells. The tubules are small in diameter, they have a thin basement membrane, and there is hyperplasia of Leydig cells. In partial hypoplasia, some



WESTERN COLLEGE OF  
VETERINARY MEDICINE



### Department of Large Animal Clinical Sciences Western College of Veterinary Medicine

David G. Wilson, DVM, Diplomate ACVS (*Editor*)  
Charles S. Rhodes, DVM, MSc (*Dean*)  
David G. Wilson, DVM, Diplomate ACVS  
(*Department Head*)

Ken Armstrong, DVM, Professor Emeritus  
Sue Ashburner, DVM  
Jeremy Bailey, BVSc, Diplomate ACVS  
Spence M. Barber, DVM, Diplomate ACVS  
Albert D. Barth, DVM, Diplomate ACT  
Frank Bristol, DVM, DACT, Professor Emeritus  
Ray Butler, DVM, Professor Emeritus  
John Campbell, DVM, DVSc  
Claire Card, DVM, DACT  
James L. Carmalt, VetMB, MRCVS, MVetSci,  
Diplomate ABVP (Equine)  
Terry D. Carruthers, DVM, PhD  
Bill Cates, DVM, Professor Emeritus  
Chris Clark, VetMB, MVetSci, Diplomate ACVIM  
Peter B. Fretz, DVM, Diplomate ACVS,  
Professor Emeritus  
Paul Greenough, DVM, Professor Emeritus  
Jerry Haigh, DVM, Diplomate ACZM  
Murray D. Jelinski, DVM, MSc  
Katharina Lohmann, DVM,  
Diplomate ACVIM, PhD  
Steve Manning, DVM, Diplomate ACT  
Fernando J. Marqués, DVM, Diplomate ACVIM  
Reuben J. Mapletoft, DVM, PhD  
Colin Palmer, DVM, Diplomate ACT  
Lyall Petrie, BVMS, PhD  
O.M. Radostits, DVM, Diplomate ACVIM,  
Professor Emeritus  
Fritz J. Schumann, DVM, MVetSci  
Joseph M. Stookey, PhD  
Hugh G.G. Townsend, DVM, MSc  
Cheryl Waldner, DVM, PhD  
Murray R. Woodbury, DVM, MSc

### Western College of Veterinary Medicine Department of Large Animal Clinical Sciences

52 Campus Drive  
University of Saskatchewan  
Saskatoon, Saskatchewan S7N 5B4

The editorial content of *Large Animal Veterinary Rounds* is determined solely by the Department of Large Animal Clinical Sciences, Western College of Veterinary Medicine



The Canadian Veterinary Medical Association recognizes the educational value of this publication and provides support to the WCVM for its distribution.

of the tubules have germinal cells and spermatogenesis within individual tubules varies from incomplete to normal. Hypoplasia must be differentiated from testicular degeneration. In degeneration, the seminiferous epithelium is vacuolated with only Sertoli cells, or with reduced numbers of germinal cell types. Advanced degenerative changes include spermiostasis, tubular mineralization, granuloma formation, thickened basement membranes, and fibrosis. Atrophy of the Leydig cells is seen when no Sertoli cells are left in the tubule. Young bulls with very small testicles are more prone to develop testicular degeneration at 2 to 3 years of age.<sup>2</sup>

Testicular hypoplasia has been studied most closely in Swedish cattle.<sup>2</sup> Classically, Swedish Highland cattle were white with large areas of black and brown on the sides of the body and with a black muzzle. At the turn of the 20th century, selection of animals with less pigmentation became popular. Breeders soon noticed that along with the change in pigmentation, the left testis was smaller than the right in some of the bulls. The affected bulls were usually fertile, so little attention was paid to the difference in size of the testes, and affected bulls were extensively used for breeding. Some bulls had bilateral testicular hypoplasia and were sterile. Gonadal hypoplasia in the Swedish Highland breed appears to be caused by an autosomal recessive gene with incomplete penetrance. The condition exists in many breeds today, although at a very low frequency. Double muscling (myofiber hyperplasia), which itself is inherited as an autosomal recessive trait, is associated with a high incidence of bilateral testicular hypoplasia.<sup>3</sup>

Most workers agree that testicular hypoplasia is congenital, possibly inherited, and caused by a marked lack of spermatogonia in the gonads during fetal life.<sup>4</sup> Primordial germ cells arise from the yolk sac endoderm in the early embryo. These germ cells are amoeboid in nature and migrate to the genital ridges on the dorsal body wall of the embryo. In the migration process, their numbers increase by mitotic division and continue to increase after reaching the genital ridge, where they form the germinal epithelium. Germinal epithelium invagination results in the formation of sex cords lying within the mesenchyme. The sex cords later become the seminiferous tubules. The primordial germ cells associate themselves with the precursor Sertoli cells that are believed to arise from the organ formative cellular matrix. Leydig cells arise from undifferentiated mesenchymal cells in the interstitium. Testis hypoplasia may be partial, or total, due to a failure of germinal cells to develop in the yolk sac, a failure to migrate to the gonad, a failure to multiply in the gonad, or due to extensive degeneration after they have entered the gonad.

The use of growth-promoting implants has the potential to impair testicular development.<sup>5</sup> When bulls were implanted with zeranol (Ralgro) at birth, at 3 months (mo), and at 6 mo of age (ie, every 3 mo up to 18 mo of age), SC and serving capacity were adversely affected, but tended to

recover with increasing age. Semen quality was also affected adversely, but did not improve with increasing age. There was no difference in testicular weight, vesicular gland weight, and penis length among treated and control groups when bulls were slaughtered at 20 mo of age. Histological examination revealed that zeranol induced adenomyosis and sperm granulomas in the cauda epididymides and markedly altered the histological structure of the sexual accessory glands. There was little effect on the reproductive organs when bulls were implanted with zeranol after 7 mo of age.

### *Klinefelter's syndrome*

Klinefelter's syndrome has been reported to affect between 1 in 500 and 1 in 800 human males. The condition is associated with the presence of more than one X chromosome. The most common form is XXY and rarest variants include XXYY and XXXY. Affected males remain more or less normal until the approach of puberty, but at that time, the testes remain small and undergo degenerative changes with hyaline sclerosis and atrophy of the seminiferous tubules. Sterility associated with the XXY genotype in domestic male mammals has been reported in dogs, sheep, pigs, cattle, and in tortoise-shell or calico cats. A Klinefelter's Charolais bull, which also had a Robertsonian 1;29 translocation, was encountered at the University of Saskatchewan.<sup>6</sup> The bull had very small testes and was azoospermic; however, he was phenotypically normal and had a normal sized penis and accessory glands.

### *Effect of a female co-twin on bull fertility*

Studies of bulls born co-twin to freemartins (sterile female) have shown that the number of XX lymphocytes in their blood varied from 5% to 95%. The effect of XX chimerism on fertility has not been well studied; however, in one study of 12 chimeric bulls in an artificial insemination (AI) centre, 58% were culled for poor semen quality associated with testicular degeneration and hypoplasia, compared to < 6% of 128 single-born bulls. One of the chimeric bulls produced calves with a markedly skewed sex ratio of 29 males to 71 females, suggestive of germ cell chimerism. In early cytogenetic studies, a few authors reported finding XX cells in the testes of young calves, however, later studies did not confirm these findings.<sup>7</sup>

### *Cryptorchidism*

The testes enter the scrotum midway through fetal life in ruminants. Cryptorchidism (undescended testis) may be bilateral, but in most cases, it is unilateral. The etiology is poorly understood, but it may involve a disruption in concentrations of gonadotropins, testosterone, and anti-Müllerian hormone in fetal life. A survey conducted in North American Veterinary Schools over a period of 26 years indicates that the overall incidence of cryptorchidism is 0.17%.<sup>8</sup> The incidence (approximately 1.0%)

is greater in polled Herefords and Shorthorns, and is 40% greater in polled bulls than in horned bulls across all breeds. Unilateral cryptorchidism is more common and the left side is affected twice as often as the right side. The affected testis can be located anywhere along the normal trajectory of descent, but is found twice as often in the inguinal canal as in the abdominal cavity. Cryptorchid testes inside the abdominal cavity are usually located close to the internal inguinal rings in bulls. Evidence in all domestic species indicates that cryptorchidism is heritable; therefore, affected bulls, their sires, and dams should be removed from the breeding herd.<sup>9</sup>

#### ***Scrotal or inguinal hernia***

The incidence of congenital inguinal hernia is high in the pig, low in the horse and dog, and rare in sheep and cattle. A definitive etiology for inguinal hernias in cattle has not been determined; however, its known inheritance in other species indicates that the condition should be selected against. Reportedly, inguinal hernias are seen most commonly in the Hereford breed and are usually left sided. Herniation into the scrotum is rarely life threatening, but it will seriously depress fertility by interfering with testis thermoregulation.

#### ***Ectopic testes***

Ectopic testes lie in a position other than in the normal line of descent. Usually, ectopic testes are in a prescrotal position along the ventral abdominal wall fairly close to the prepuce, or on the inner aspect of the upper part of the thigh. They are found subcutaneously, covered only by skin and a layer of connective tissue.<sup>2</sup>

#### ***Short scrotum, caudal frenulum of the scrotum, rotated scrotum***

Although many veterinarians have observed bulls in which the testes appear to be held too close to the body due to an abnormally short scrotum or a pronounced caudal frenulum of the scrotum, these abnormalities do not appear to be reported in the literature. In our observations, a short scrotum with no neck or an inadequate neck for normal testis thermoregulation, is not common in bulls. In bulls < 2 years of age, a short scrotum may be associated with testes of any size. In many cases, when yearling bulls with short scrotums, but average-to-large sized testes are maintained to an age of  $\geq 18$  mo, the scrotum gradually lengthens and a scrotal neck develops. In some cases, normal spermatogenesis occurs after the scrotum lengthens, but in others, poor semen quality may remain indefinitely.

A caudal frenulum of the scrotum has not been associated with abnormal spermatogenesis in most cases we have observed. In rare cases, a very pronounced caudal frenulum of the scrotum resulted in an almost horizontal tilting of the testes, which were held close to the body. In these cases,

unsatisfactory semen quality may be due to abnormal thermoregulation of the testes.

#### ***Vascular malformation of the spermatic cord***

There are few reports of vein varicosity in the spermatic cord of domestic mammals. The condition occurs most often in the ram and is rare in the bull. In 2 mature Charolais bulls, we observed unilateral, 3 to 5 cm enlargements in the spermatic cord that felt like varicoceles or appeared to be varicoceles on ultrasound examination. Semen quality was poor in one bull, but satisfactory in the other.

#### ***Testicular degeneration***

Testicular degeneration may be focal or diffuse, and unilateral or bilateral. Gross lesions may not be clinically evident in mild-to-moderate cases of testicular degeneration. In cases of advanced degeneration, the testes become reduced in size and may feel softer than normal or fibrotic. It is often difficult to discern the difference in texture between fibrotic testicles and normal testicles by palpation; however, ultrasonography will readily reveal fibrotic changes and even mild degeneration of seminiferous tubules may be detected by changes in pixel intensity.

Testicular degeneration has a variety of causes. The more common causes include abnormal thermoregulation, nutritional deficiencies, aging, trauma, orchitis, and obstruction of efferent ducts.

*Thermoregulation:* The most common cause of abnormal thermoregulation is an accumulation of fat in the scrotum. Other causes include scrotal frostbite, scrotal dermatitis, and a short scrotum. An increase in testis temperature by  $0.5^{\circ}$  to  $1^{\circ}\text{C}$  for a few days is sufficient to cause a noticeable disturbance of spermatogenesis. Normally, because of the peculiar anatomy of the blood supply to the testis, the testis operates on the brink of hypoxia. Raising testicular temperature increases the metabolic activity, but there is no corresponding increase in blood supply and tissue hypoxia ensues. Spermatocytes and the spermatids are the most sensitive to injury, but with sufficient severity and duration of the hypoxic state, all of the germinal cells and even the Sertoli cells can be destroyed.

*Nutrition:* Nutritional deficiencies seldom involve only one type of nutrient, but rather involve multiple nutrient deficiencies, eg, protein and energy along with certain vitamins and minerals. General debility associated with prolonged nutritional deficiency may result in testicular degeneration. Vitamin A deficiency has been shown to cause testicular degeneration in several species including the bull.

*Orchitis:* Orchitis may be accompanied by periorchitis and epididymitis. Bacterial invasion may develop hematogenously, through retrograde migration from the ductus deferens and epididymis, or directly through wounds of the scrotal skin. The swollen scrotum of affected bulls is hot and doughy and may become filled with a fibrinopu-

ruent exudate. If orchitis is treated early with antibiotics, recovery may occur quickly without lasting damage to the testicles.

### **Testicular neoplasms**

Testicular neoplasms are rarely encountered in bulls.<sup>2</sup> Tumours may be undetectable by palpation, but can usually be observed by ultrasonography. The most common type of tumour in bulls is the interstitial (Leydig) cell tumour. This tumour is usually benign and is more common in bulls >5 years old, although it has also been described in young calves. Larger interstitial cell tumours are yellow-gray to orange, spherical, and well demarcated from surrounding tissue. One study indicated that sperm production and fertility were adversely affected when tumours were >1 cm in diameter.

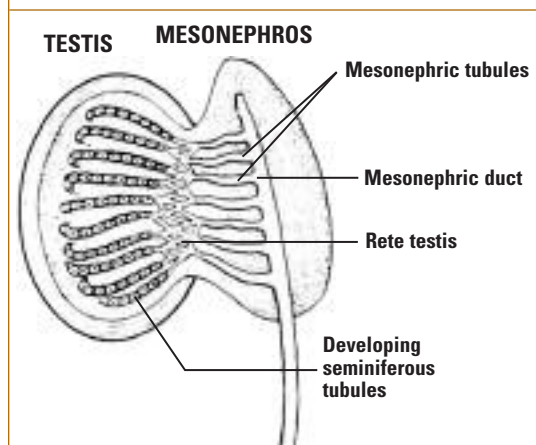
Sertoli cell tumours are pale gray, firm neoplasms that usually result in enlargement of the affected testis. In a study of 26 affected bulls, varying in age from 1 to 12 years, 3 bulls with large Sertoli cell tumours had metastatic lesions in the regional lymph nodes. Most reports concerning Sertoli neoplasia in bulls involve the Shorthorn breed.<sup>9</sup> In one report, 2 newborn Shorthorn calves had a single enlarged gonad in the scrotum at birth.<sup>10</sup> The occurrence of this rare tumour in 2 calves sired by a single bull suggests a genetic basis. Sertoli cell tumours are known to cause feminization in dogs due to the production of estrogen; however, an estrogenic effect has not been reported in bulls. Seminomas have not been reported in bulls.

### **Hydrocele and hematocele**

Accumulation of fluid or blood within the scrotal lumen is uncommon in domestic mammals. Hydroceles can be unilateral or bilateral. The cause of a hydrocele is unknown, but several causes have been postulated including ascites, trauma, hot weather, and neoplasms. In one case, a scrotal hydrocele occurred secondary to ascites caused by a liver fluke infection. Hydrocele is often associated with a depression in semen quality. Spontaneous recovery has been reported in about 80% of cases within 4 months of diagnosis and with a return to normal sperm production.<sup>11</sup>

Hematoceles may be due to trauma to the testis or secondary to hemorrhage in the peritoneal cavity. With trauma to the testis, the hematocele is usually unilateral with a marked distension of the scrotum. Over a period of months, the injury is resolved by organization and resorption of the clot, followed by fibrosis and degeneration of the affected testis.

**Figure 1: Embryonic development of the epididymis (mesonephric duct) and efferent ductules (mesonephric tubules).**



### **Conditions of the efferent ductules, epididymis, and vas deferens**

In the adult, the seminiferous tubules empty into a system of collecting tubules known as the rete testis. In bulls, the rete testis empties at the dorsal pole of the testis into the efferent ductules that were derived from the embryonic mesonephric tubules. The efferent ductules number about 15; they are long, convoluted, and make up a large portion of the caput epididymis. They absorb 90% of the fluid produced by the testis. Individual efferent ductules consist of 3 segments: a nearly straight part that leaves the rete testis, a long, highly convoluted central section, and a moderately convoluted terminal segment that enters the epididymis. The efferent ductules empty into a single tube – the epididymis – which is about 120 feet long. Figure 1 illustrates the embryonic formation of the connection between the seminiferous tubules and the epididymis.

### **Blind-ending efferent ductules**

If the mesonephric tubules fail to connect to the rete tubules, then blind-ending mesonephric (efferent) ductules result. When sperm production is initiated, these may become impacted with sperm. Impacted ductules may rupture releasing spermatozoa that are immunologically foreign; hence, a tissue reaction occurs resulting in granuloma formation.

Blind-ending efferent ductules occur frequently in domestic animals. In one report, 8 of 25 bulls were affected.<sup>12</sup> Affected bulls had 1 to 5 blind-ending ductules; however, the number of blind-ending ductules needed to cause spermiostasis is unknown. There is considerable evidence that bovine spermiostasis in the efferent ductules is genetically determined by a recessive

sive hereditary factor. Spermatic granulomas develop slowly, thus young, even bilaterally-affected, males may be fertile for a year or more until the fibrous tissue of the granuloma completely obstructs the efferent ductules. Efferent ductule granulomas result in enlargement of the caput epididymis. If most or all of the efferent ductules are obstructed, the testes become enlarged and edematous, and degeneration follows.

### **Aplasia of the epididymis**

Blom and Christensen<sup>13</sup> conducted examinations on 2,000 bulls; the majority of the bulls were of the Red Danish breed. Aplasia of the epididymis and/or vas deferens was found in 7 bulls. The lesions occurred on the right side in 6 bulls and on the left side in 1 bull. Aplasia of the vesicular gland was diagnosed in 4 bulls and it occurred on the side with the affected epididymis. König and coworkers reported the occurrence of epididymal aplasia in 18 Simmental bulls: both epididymides were affected in 12 bulls, 3 had left-sided aplasia, and 3 had right-sided aplasia.<sup>14</sup> They concluded from the genealogical data that an autosomal recessive gene was responsible for the condition. Epididymal aplasia has been reported by others in many different breeds.

Segmental aplasia of the epididymis or ductus deferens has been well described in bulls. There is a strong indication that segmental aplasia is hereditary; in 19 male offspring of a unilaterally-affected bull, 4 sons were similarly affected.<sup>2</sup> The missing segment was most often lacking on the right side. In older bulls, spermatoceles and/or granulomas may develop just proximal to the missing segment. Palpation of a very small or missing tail of the epididymis is highly indicative of aplasia, or segmental aplasia of the epididymis.

### **Lesions of the appendix epididymis**

The appendix epididymis is a vestigial remnant of part of the embryonic mesonephric duct. The appendix epididymis may form a cyst that is usually located between the head of the epididymis and the testis but, occasionally, it is present on the surface of the testis adjacent to the head of the epididymis. Very large cysts may be present between the epididymis and the testis in older animals. They do not interfere with the function of the epididymis because they enlarge very slowly over a long time and do not block the movement of sperm.

### **Epididymitis due to sperm stasis**

Sperm granulomas may cause marked enlargement of the head of the epididymis. Spermatic granulomas develop secondary to sperm stasis in blind efferent ductules, to the accumulation of sperm in aberrant

epididymal ducts, to sperm stasis secondary to adenyosis of the epididymis, and secondary to infectious epididymitis. Sperm contain acid-fast material that evokes a granulomatous response similar to that induced by mycobacteria. An inflammatory reaction develops when sperm escape from the ductal system. This inflammatory process can become self-perpetuating, since granulomas cause obstruction of other components of the ductal system. Spermatic granulomas due to congenitally blocked ductules start to develop in sexually mature young animals, whereas acquired blockages may occur at any age after maturity.

Blom and Christensen examined the reproductive organs of 2,285 bulls and found spermiostrasis in the ductuli efferentes of 2.1% of Danish Friesian bulls and 3.9% of Red Danish bulls.<sup>15</sup>

### **Epididymitis due to infection**

Wide varieties of bacteria, including *Chlamydia* and *Mycoplasma* have been implicated in infectious epididymitis. A specific viral disease, "epivag," is found only in Africa where it causes vaginitis and epididymitis. Bacterial epididymitis is usually unilateral and, more commonly, appears to affect the cauda epididymis. In long-standing cases, the lesions may extend into the body and head of the epididymis. Epididymitis is often associated with vesicular adenitis. The effect of cauda epididymitis on semen quantity and quality ranges from no noticeable effect to poor semen quality and oligospermia. Ultrasonography of the ampullae may be used to determine whether epididymal blockage has occurred; empty ampullae indicate a lack of sperm flow from the cauda epididymis. Recovery from cauda epididymitis may occasionally occur spontaneously or after antibiotic treatment; however, antibiotic treatment frequently fails to cure epididymitis. There are no reports in the literature regarding the success rate for antibiotic treatment.

---

*Dr. Albert Barth graduated from the Department of Large Animal Clinical Sciences at the Western College of Veterinary Medicine (WCVM), Saskatoon, Saskatchewan. He is currently a Professor of Theriogenology at the WCVM.*

---

### **References**

1. Johnson BH. Effects of hemicastration on testicular functions in adult and young pubertal bulls. *Theriogenology* 1978;10:257-264.
2. McEntee K. *Reproductive pathology of domestic mammals*. San Diego, CA: Academic Press; 1990.
3. Michaux C, Van Sicheem-Reynaert R, Beckers JF, et al. Endocrinological studies on double muscled cattle; LH, GH, testosterone and insulin plasma levels in the first year of life. In: King JWB, Menissier F, eds. *Muscle hypertrophy of genetic origin and its use to improve beef production*. London: Martinus Nishoff; 1982: 350-359.
4. Steffen DS. Genetic causes of bull infertility. *Vet Clin North Am Food Anim Pract* 1997;13:243-53.

5. Deschamps JC, Ott RS, McEntee K, et al. Effects of zeronal on reproduction in beef bulls: Scrotal circumference, serving ability, semen characteristics, and pathological changes in the reproductive organs. *Am J Vet Res* 1987;48:137-147.
6. Schmutz SM, Barth AD, Moker JS. A Klinefelter bull with a 1:29 translocation born to a fertile 61,XXX cow. *Can Vet J* 1994;35:182-184.
7. Dunn HO, McEntee K, Hall CE, Johnson RH Jr, Stone WH. Cytogenetic and reproductive studies of bulls born co-twin with freemartins. *J Reprod Fertil* 1997;57:21-30.
8. Jean GS, Gaughan EM, Constable PD. Cryptorchidism in North American cattle: breed predisposition and clinical findings. *Theriogenology* 1992;38:951-58.
9. Ladds PW. The male genital system. In: Jobb KVE, Kennedy PC, Palmer N, eds. *Pathology of domestic animals*. San Diego: Academic Press: 1993: 471-529.
10. Palmer NC, King AB, Basur PK. Sertoli cell tumour in two related newborn Shorthorn calves. *Can Vet J* 1980;21:317-319.
11. Abbitt B, Fiske RA, Craig TM, et al. Scrotal hydrocele secondary to ascites in 28 bulls. *J Am Vet Med Assoc* 1995;207: 753-756.
12. Hemeida NA, Sack WO, McEntee K. Ductuli efferentes in the epididymis of boar, goat, ram, bull, and stallion. *Am J Vet Res* 1978;39: 1892-1900.
13. Blom E, Christensen NO. Studies on pathological conditions in the testis, epididymis, and accessory glands in the bull. *Skand Vet Tidsskr* 1947;37:1-49.
14. König H, Weber W, Kupferschmied H. Aplasia of the epididymis in the bull. *Schweiz Arch Tierheilkd* 1972;114:73-82.
15. Blom E, Christensen NO. The etiology of spermioastasis in the bull. Studies on pathological conditions in the testis, epididymis, and accessory glands in the bull. *Nord Veterinaermed* 1960;12: 453-470.

## Abstract of Interest

### Mutations in myostatin (GDF8) in double-muscled Belgian Blue and Piedmontese cattle.

KAMBADUR R, SHARMA M, SMITH TP, BASS JJ.  
HAMILTON, NEW ZEALAND.

A visibly distinct muscular hypertrophy (mh), commonly known as double muscling, occurs with high frequency in the Belgian Blue and Piedmontese cattle breeds. The autosomal recessive mh locus causing double-muscling condition in these cattle maps to bovine chromosome 2 within the same interval as myostatin, a member of the TGF-beta superfamily of genes. Because targeted disruption of myostatin in mice results in a muscular phenotype very similar to that seen in double-muscled cattle, we have evaluated this gene as a candidate gene for double-muscling condition by cloning the bovine myostatin cDNA and examining the expression pattern and sequence of the gene in normal and double-muscled cattle. The analysis demonstrates that the levels and timing of expression do not appear to differ between Belgian Blue and normal animals, as both classes show expression initiating during fetal development and being maintained in adult muscle. Moreover, sequence analysis reveals mutations in heavy-muscled cattle of both breeds. Belgian Blue cattle are homozygous for an 11-bp deletion in the coding region that is not detected in cDNA of any normal animals examined. This deletion results in a frame-shift mutation that removes the portion of the Myostatin protein that is most highly conserved among TGF-beta family members and that is the portion targeted for disruption in the mouse study. Piedmontese animals tested

have a G-A transition in the same region that changes a cysteine residue to a tyrosine. This mutation alters one of the residues that are hallmarks of the TGF-beta family and are highly conserved during evolution and among members of the gene family. It therefore appears likely that the mh allele in these breeds involves mutation within the myostatin gene and that myostatin is a negative regulator of muscle growth in cattle as well as mice.

*Genome Res* 1997;7:910-6.

## Upcoming Meetings

31 May – 3 June 2006

**2006 American College of Veterinary Internal Medicine (ACVIM) Forum**  
Louisville, KY

Contact: Tel.: 800 245-9081; 303 231-9933

Fax: 303-231-0880

Email: ACVIM@ACVIM.org

Web site: www.acvim.org

8 – 10 June 2006

**WCVIM/SVMA June Conference**

Saskatoon, Saskatchewan

Contact: www.usask.ca/wcvim/juneconf/about.php

22 – 26 August 2006

**Society for Theriogenology (SFT)/ American College of Theriogenologists (ACT) Conference and Symposium**

St. Paul, Minnesota

Contact: therio.org

17 – 21 September 2006

**International Veterinary Emergency and Critical Care Symposium**

San Antonio, Texas

Contact: www.veccs.org

15 – 19 October 2006

**24th World Buiatrics Conference**

Nice, France

Contact: Service Gestion des congrès

Tel: 00 33 (0)4 93 92 81 61/58

Fax: 00 33 (0)4 93 92 83 38

E-mail : wbc2006@nice-acropolis.com

Website: www.wbc2006.com

*Dr. Barth has stated that he has no disclosures to announce in association with the contents of this issue.*

Change of address notices and requests for subscriptions to *Large Animal Veterinary Rounds* are to be sent by mail to P.O. Box 310, Station H, Montreal, Quebec H3G 2K8 or by fax to (514) 932-5114 or by e-mail to info@snellmedical.com. Please reference *Large Animal Veterinary Rounds* in your correspondence. Undeliverable copies are to be sent to the address above. Publications Post #40032303

This publication is made possible by an educational grant from

**Schering-Plough Animal Health**

© 2006 Department of Large Animal Clinical Sciences, Western College of Veterinary Medicine, which is solely responsible for the contents. The opinions expressed in this publication do not necessarily reflect those of the publisher or sponsor, but rather are those of the authoring institution based on the available scientific literature. Publisher: SNELL Medical Communication Inc. in cooperation with the Department of Large Animal Clinical Sciences, Western College of Veterinary Medicine. <sup>TM</sup>*Large Animal Veterinary Rounds* is a Trade Mark of SNELL Medical Communication Inc. All rights reserved. SNELL Medical Communication Inc. is committed to the development of superior Continuing Medical Education. The administration of any therapies discussed or referred to in *Large Animal Veterinary Rounds* should always be consistent with the recognized prescribing information in Canada.